Research Journal of Surgery
Abbr. Title: Res J Surg
ISSN(Online): XXXX-XXXX

OPEN ACCESS

Research Article
Volume-01 | Issue-01 | 2022

Ultrasonography of Human Masseter

*Assoc. Prof. Fouzi Boukhazani*1, Dr. Khalil Djebara1, Dr.Hamma Rouaimia1, Dr Ahmed Babziz1, Pr. Fatma Siahmed1*

1Faculty of Medicine of Ouargla, Algeria

Received 12-03-2022
Accepted 16-04-2022
Published 15-05-2022

Abstract: The human masseter is a symmetric muscle known to be a strong elevator muscle of the lower jaw. The actual pilot study aims to check the applicability of a new imaging technique for this muscle to facilitate diagnosis and treatment for clinicians working on this part of human body.
91 Patients, aged from 8 to 12 years old, participated in this study in which an ultrasonography was accomplished. The visibility of sub-cutaneous plane, the visibility of the deep plane represented by the ramus and the visibility of masseter's layers have been evaluated.
At the end of this study, all the young patients were examined without any issue. The deep plane was easily distinguished in 98.90% of the participants while the superficial plane was visible in 87.91% of the participants. The different layers were visible in 95.60% in contraction examination compared to 84.61% in rest examination.
The viability of ultrasonography of masseter has been reported by authors. Bakke et al. in 1992 considered that ultrasound scanning gave an uncomplicated and a reproducible access to parameters of jaw muscle function. The findings of the current study confirm that ultrasonography can be employed to evaluate the thickness of masseters with acceptable reliability.
In conclusion, the introduction of ultrasonography in the masticatory muscles imaging can be a real breakthrough in diagnosis and treatment techniques used by clinicians.

Keywords: Masseter, Ultrasonography, Reliability, Rest, Contraction

INTRODUCTION

The human masseters are pair of muscles known to be strong elevators of the lower jaw. In addition to their physiological role, the masseters can be an etiology for some disorders. Several techniques have been proposed to study these muscles and to evaluate their functional status. They are usually evaluated by biomechanical techniques such as bite force (1,2) measurement or electrical techniques such as Electromyography (EMG) (3–5). Imaging techniques are commonly used also such as CT scans(6) and MRI (7). Some authors reported Immunohistochemistry (IHC) to be a highly precise technique for masseter's study (8).

Background

Although the techniques reported in the literature to study masseters, some disadvantages were noticed (9):

- Need for specific equipment
- Subjective measurement
- Some results are irreproducible
- Inappropriate for children
- Use of high doses of X Rays
- Need for biopsy

The actual pilot study aims to check the applicability of a new imaging technique for masseter muscle to facilitate diagnosis and treatment for clinicians working on this part of human body without the disadvantaged noticed in other techniques.

METHODS

In this study, 91 patients (53 girls and 38 boys), aged from 8 to 12 years old, received an ultra-sound exam in masseters area.

For this examination, the following equipment has been used:

- Esaote™ MyLab50® ultrasound machine (made in Italy) (Fig 1).
- 12MHz Ultrasonography Linear Probe.

***Figure 1** : Ultra-sound machine Esaote™ MyLab50®*

For the examination of the both masseters, the probe is moved on the skin of the face from the lower border of the lower jaw bone to the zygomatic arch (Fig 2).

***Corresponding Author:** Fouzi Boukhazani

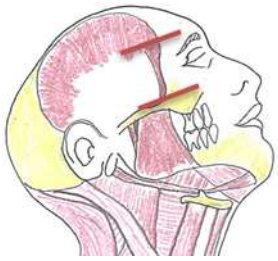

Figure 2: The borders of the scan

Quality criteria for the exam of masseters were evaluated.

RESULTS

The mean age of the participants in this study is 10.48±1.31 years old. The evaluation criteria for the masseter examination are:

- The visibility of superior muscle fascia,
- The visibility of the deep plane represented by the bone
- The visibility of masseter's layers at rest
- The visibility of masseter's layers in contraction

The visibility of superior muscle fascia

The superior muscle fascia was clearly visible in 80 (88%) participants (Fig 3. A).

The visibility of deep plane:

The deep plan represented by ramus bone was clearly visible in 90 participants (Fig 3. B).

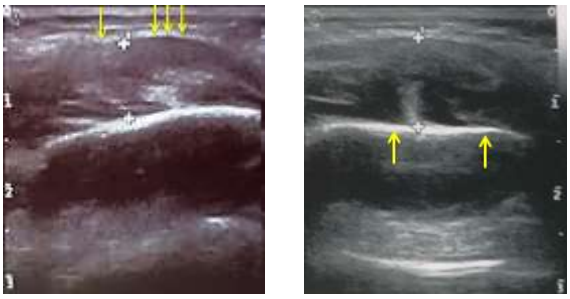

A B

***Figure 3**: The muscle superficial and deep limits*

The masseter's layers:

The muscle's layers were visible in 77 participants at rest and in 87 participants in contraction of masseters (Fig 4).

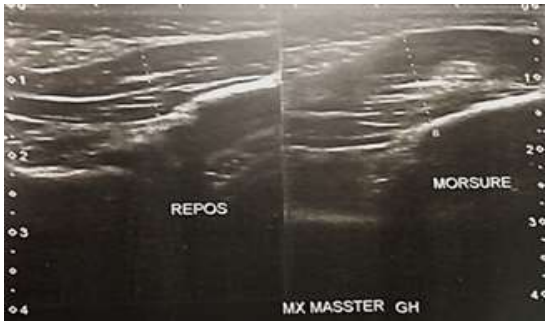

***Figure 4**: The layers visibility at rest and in contraction*

The following table summarizes the results of the current study:
n: number of participants
p: proportion of participants

***Table 1:** The results of the actual study*

The parameters	Visible		Invisible	
	n	P	n	P
Superior fascia	80	87,91%	11	12,09%
Deep plane	90	98,90%	1	1,10%
Layers at rest	77	85,55%	14	14,45%
Layers in contraction	87	95,60%	4	4,40%

DISCUSSION

The viability of ultra-sound imaging of masseter has been reported by authors.

Bakke et al. in 1992 considered that ultrasound scanning gave an uncomplicated and a reproducible access to parameters of jaw muscle function (10).

The findings of the current study confirm that ultrasonography can be employed to evaluate the thickness of masseters with acceptable reliability. This is confirmed by the visibility of superficial plane in 87,91% and the deep plane in 98,90% of the participants. The better visibility of the deep plane compared to the superficial one is explained by the difference of visibility of hard tissues compared to soft tissues because the deep plane is represented by the bone of the ramus.

The muscle's layers have been evaluated because they are usually used to diagnose some pathological aspects of the masseters.

In addition to physiological aspects studied in the current study, other authors as Naphade *et al.* used ultrasonography in diagnosis of some pathological aspects of the masseter (11).

Recently, masseter ultrasound has been used for guidance in botulinum neurotoxin chemodenervation procedures in bruxism therapy for example (12).

CONCLUSION

The introduction of ultrasonography in the masticatory muscles imaging can be a real breakthrough in diagnosis and treatment techniques used by clinicians.

But further studies are needed in other age groups to evaluate the parameters of convenient visibility of the muscles.

REFERENCES

1. Sondang, P., Kumagai, H., Tanaka, E., Ozaki, H., Nikawa, H., Tanne, K., & Hamada, T. (2003). Correlation between maximum bite force and craniofacial morphology of young adults in Indonesia. *Journal of oral rehabilitation*, *30*(11), 1109-1117.
2. Sonnesen, L., & Bakke, M. (2005). Molar bite force in relation to occlusion, craniofacial dimensions, and head posture in pre-orthodontic children. *The European Journal of Orthodontics*, *27*(1), 58-63.
3. Farella, M., Michelotti, A., Carbone, G., Gallo, L. M., Palla, S., & Martina, R. (2005). Habitual daily masseter activity of subjects with different vertical craniofacial morphology. *European journal of oral sciences*, *113*(5), 380-385.
4. Serrao, G., Sforza, C., Dellavia, C., Antinori, M., & Ferrario, V. F. (2003). Relation between vertical facial morphology and jaw muscle activity in healthy young men. *Progress in orthodontics*, *4*(1), 45-51.
5. Tecco, S., Caputi, S., & Festa, F. (2007). Electromyographic activity of masticatory, neck and trunk muscles of subjects with different skeletal facial morphology–a cross-sectional evaluation. *Journal of oral rehabilitation*, *34*(7), 478-486.
6. Weijs, W. A., & Hillen, B. (1986). Correlations between the cross-sectional area of the jaw muscles and craniofacial size and shape. *American journal of physical Anthropology*, *70*(4), 423-431.
7. Van Spronsen, P. H., Weijs, W. A., Valk, J., Prahl-Andersen, B. V., & Van Ginkel, F. C. (1989). Comparison of jaw-muscle bite-force cross-sections obtained by means of magnetic resonance imaging and high-resolution CT scanning. *Journal of Dental Research*, *68*(12), 1765-1770.
8. Raoul, G. (2008). *Plasticité du masseter humain: relation entre les chaînes lourdes de myosine et la dysmorphose dento-maxillo-faciale* (Doctoral dissertation, Lille 1).
9. BOUKHAZANI, F., & Si Ahmed, F. (2021). *Etude de l'impact de la force de morsure molaire maximale et de l'épaisseur des muscles masticateurs sur les dimensions faciales verticales et transversales* (Doctoral dissertation).
10. Bakke, M., Tuxetv, A., Vilmann, P., Jensen, B. R., Vilmann, A., & Toft, M. (1992). Ultrasound image of human masseter muscle related to bite force, electromyography, facial morphology, and occlusal factors. *European Journal of Oral Sciences*, *100*(3), 164-171.
11. Naphade, V. V., Kedia, S. G., Patil, P., & Khare, S. (2018). Ultrasonographic diagnosis of benign masseter muscle hypertrophy: A case report. *Journal of Cancer Research and Therapeutics*, *14*(12), 1237.
12. Alter, K. E., & Karp, B. I. (2017). Ultrasound guidance for botulinum neurotoxin chemodenervation procedures. *Toxins*, *10*(1), 18.